



MICROENDODONTIC ANALYSIS OF FAILURE: IDENTIFYING MISSED CANALS

by Clifford J. Ruddle, D.D.S.

Mao Tse Tung wrote, "The foundation of success is failure." Clinicians who strive for endodontic excellence appreciate the elements that comprise success and use these criteria to evaluate the causes of failure.

Endodontic failures occur for a variety of reasons, but what all failures share in common is leakage.¹ Endodontic failures may generate confusion, anxiety, and frustration for clinicians and patients. Focusing the patient's attention on the stepping stones to endodontic health alleviates concerns and creates a clinical pathway to successful retreatment. Certainly, missed canals hold irritants that inevitably contribute to clinical symptoms, attachment apparatus diseases, and radiographic lesions of endodontic origin.²

There are several essential elements that, in concert, contribute to predictably successful endodontics. Diagnosis is fundamental for identifying pulpally involved teeth. It is accomplished by vital pulp tests, clinical observations, and

radiographic analyses. Critical elements of endodontic treatment that build successful outcomes include: isolation, complete access,³ identification of the orifice, orifices, or displaced orifices, performing cleaning and shaping procedures,⁴ and consistently producing preparations that can be packed three-dimensionally.⁵ Finally, restorations must be esthetic, prevent microleakage, and protect the tooth.

Historically, regrettably, and still too often, endodontic surgery is selected to resolve failures. Even with the improvements achieved in surgical endodontics in recent years, surgery is limited in its ability to predictably eliminate pulp, bacteria, and related irritants from the root canal system. Many significant advantages result when failing endodontic cases are nonsurgically re-entered.⁶ Endodontic failures can be evaluated for coronal leakage, fractures, and missed orifices/canals. Most importantly, these root canal systems can be recleaned, shaped, and packed three-dimensionally.^{3,4} Consultations should be directed toward communicating the critical importance of disassembly, the cost of this approach compared to less effective treatment choices, and improved longterm results.

The following case shows the rationale for nonsurgical endodontic retreatment, illustrates certain disassembly techniques, and emphasizes the clinical benefits of treating previously missed root canals.

CLINICAL CASE

A 45-year-old male was referred for endodontic evaluation of his lower right second molar, tooth #31. Clinical evaluation revealed this tooth was tender to percussion and was the posterior abutment for a three-unit bridge. Radiographic evaluation revealed full-gold coverage, three posts, previous endodontics, underextension of gutta percha, and a frank periapical lesion (*Figure 1*). Additionally, pre-operative radiographs taken from different angles suggested a possible extra system in the mesial root.

Nonsurgical root canal treatment was recommended due to poor marginal adaptation of the crown, suspicion of coronal leakage, underextension of gutta percha, and suspicion of

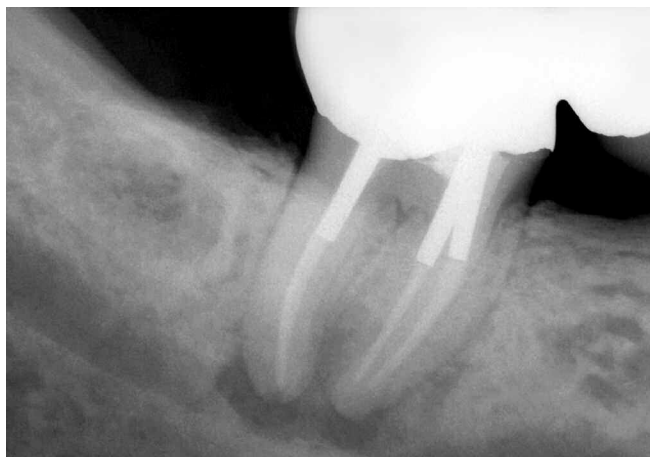

Figure 1. A pre-operative radiograph of a mandibular right second molar bridge abutment demonstrates three posts, previous endodontics, and apical pathology.

unusual anatomy. Disassembly involved sectioning the bridge at the contact point – distal to the anterior abutment – and removing the pontic and posterior abutment crown with a Peerless Crown-A-Matic (Henry Schein). Evaluating the isolated tooth revealed a bulbous crown and build-up toward the mesiolingual aspect of the tooth (Figure 2). First, the build-up was sectioned buccal to lingual and subsequently central to mesial dividing the core into three parts (Figures 3 and 4). A diamond bur eliminated the coronal-most aspect of the core, improved visibility, and afforded additional access to the pulp chamber (Figure 5). Sectioning the internal core within the pulp chamber facilitates deeper access and expands disassembly potential (Figure 6). Piezoelectric ultrasonics (Dentsply Tulsa Dental) activates a variety of new ultrasonic instruments (ProUltra ENDO Tips, Dentsply Tulsa Dental) that are designed to promote improvement in disassembly procedures. These ultrasonic instruments provide unsurpassed energy and visibility during efficient and safe elimination of restorative materials (Figures 7 and 8). Smaller profile ultrasonic instruments are selected to remove cement below the orifice level in asymmetrical canals.

The clearly visualized posts were removed with an ultrasonic instrument, designed and machined to improve contact and power at its distal end (Figure 9). An extra orifice was identified

toward the mesiolingual, and this canal system was negotiated and prepared (Figure 10). Gutta percha was removed from the MB, ML, and D systems, blockages were negotiated, and canal patencies were confirmed. All canals were cleaned, shaped, and packed using warm gutta percha with a vertical condensation technique (Figure 11). A post-operative film demonstrates the effort with the MB and ML canals superimposed over the more lingually positioned system (Figure 12). Within 48 hours, tooth #31 was asymptomatic, and the patient was referred back to the general dentist for restorative procedures.

CONCLUSION

The etiology of endodontic failure is multifaceted, but a statistically significant percent of failures are related to missed root canal system anatomy. Surgical treatment is directed toward corking the root and hoping to incarcerate biological irritants within the root canal system throughout the patient's life. Although this clinical scenario occurs anecdotally, it is not nearly as predictable as nonsurgical retreatment. Endodontic prognosis is maximized in teeth where root canal systems are cleaned, shaped, and packed in all dimensions. Properly performed endodontics is the cornerstone of restorative as well as reconstructive dentistry. ▲

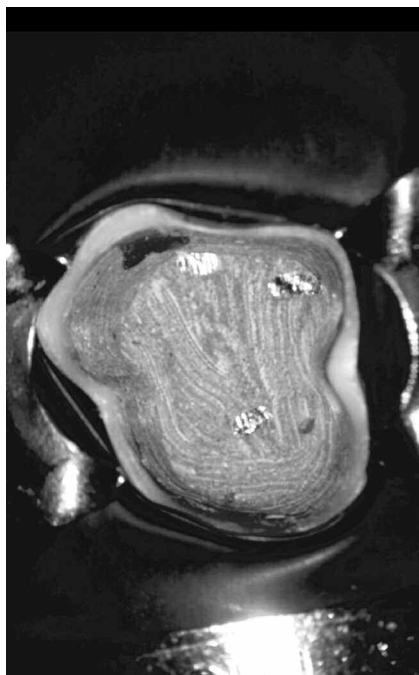


Figure 2. Following coronal disassembly, the isolated tooth reveals the core, the heads of three posts, and a marked protuberance toward the mesiolingual aspect of the crown.

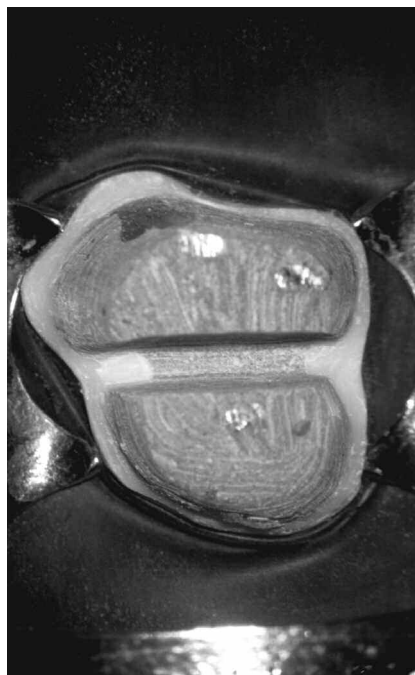

Figure 3. The core is sectioned buccal to lingual, dividing the build-up into mesial and distal halves.




Figure 4. The core is further sectioned central to mesial, dividing the build-up into thirds.

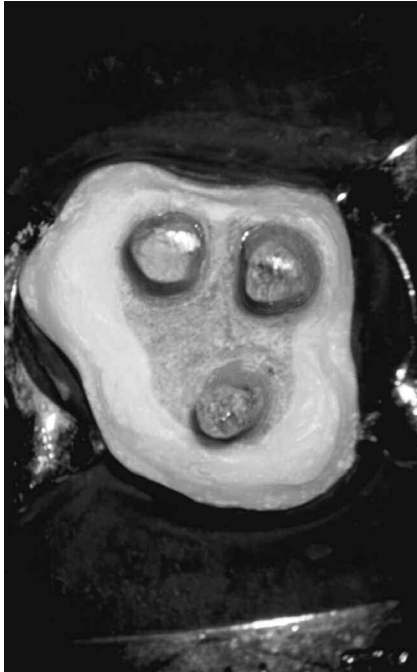

Figure 5. A diamond bur reduces the build-up, providing deeper access into the pulp chamber.

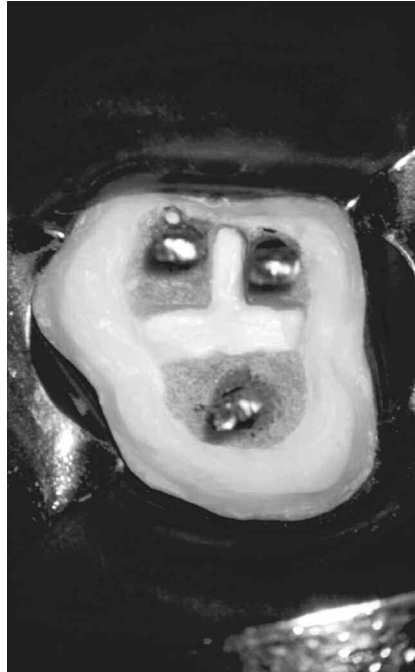


Figure 6. Within the pulp chamber, the core is carefully sectioned into thirds.

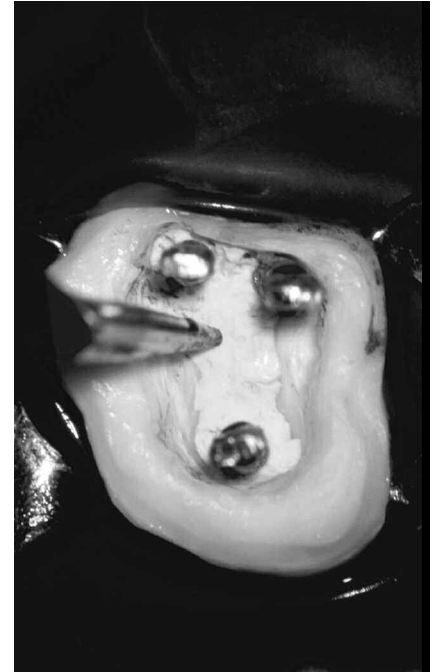


Figure 7. A ProUltra ENDO ultrasonic instrument (first generation) progressively eliminates restorative materials, thus enhancing deeper access.

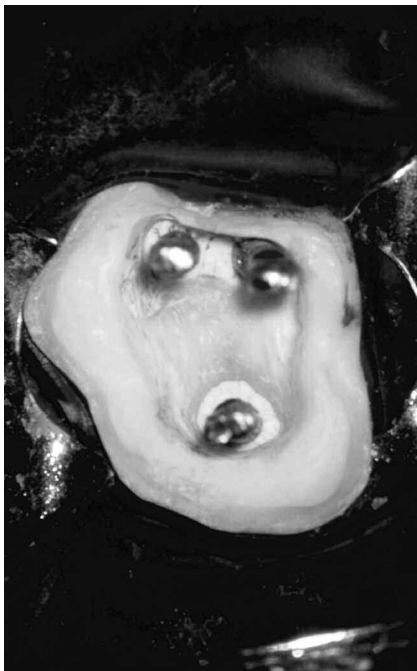

Figure 8. The pulpal floor is liberated of restorative materials, and the posts are free above the orifices.

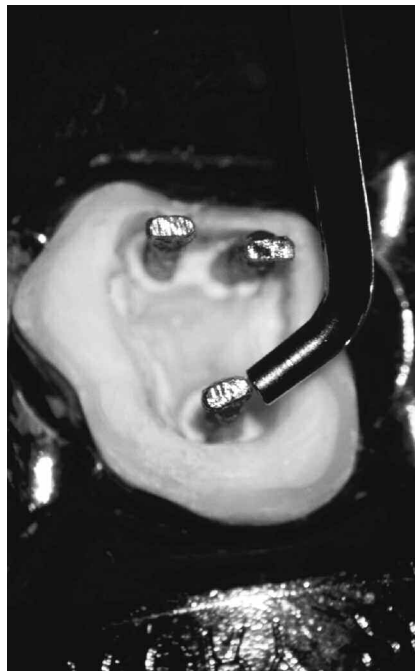

Figure 9. The ProUltra ENDO-1 (first generation) ultrasonic instrument is uniquely designed for power, efficiency, and safety during post removal.

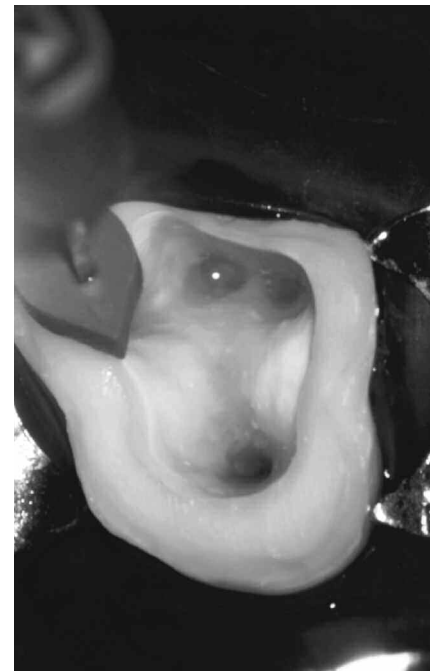

Figure 10. Following post removal, cement was removed from the mesiolingual aspect of the pulpal floor, and a displaced extra root canal system was identified.

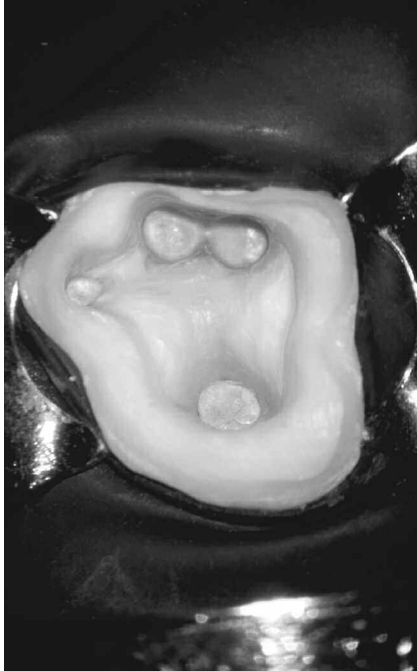


Figure 11. The pulpal floor is observed following three-dimensional cleaning, shaping, and obturation procedures.

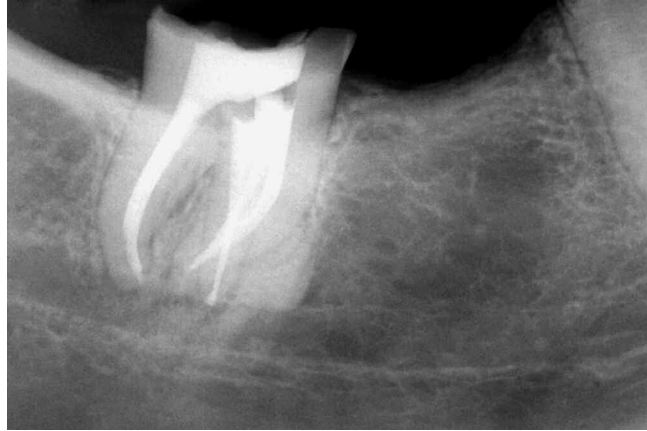


Figure 12. A mesially angulated post-operative film confirms the disassembly efforts, demonstrates the pack, and the extra, displaced, most lingual system.

REFERENCES

1. West JD: Endodontic failures marked by lack of three-dimensional seal, *The Endodontic Report* Fall/Winter, p. 9, 1987.
2. Ruddle CJ: Radiographic lesions of endodontic origin: significance of location, *The Endodontic Report* Spring/Summer, p. 10, 1987.
3. Ruddle CJ: MB2 root canal systems in maxillary first molars, *Dentistry Today* 14:5, pp. 38-40, 1995.
4. Ruddle CJ: Endodontic canal preparation: breakthrough cleaning and shaping strategies, *Dentistry Today* 13:2, pp. 44-49, 1994.
5. Ruddle CJ: Three-dimensional obturation of the root canal system, *Dentistry Today* 11:3, pp. 28-33, 39, 1992.
6. Scianamblo MJ: Endodontic failures: the retreatment of previously endodontically treated teeth, *Revue D'Odontologie Stomatologie* 17:5, pp. 409-423, 1988.